

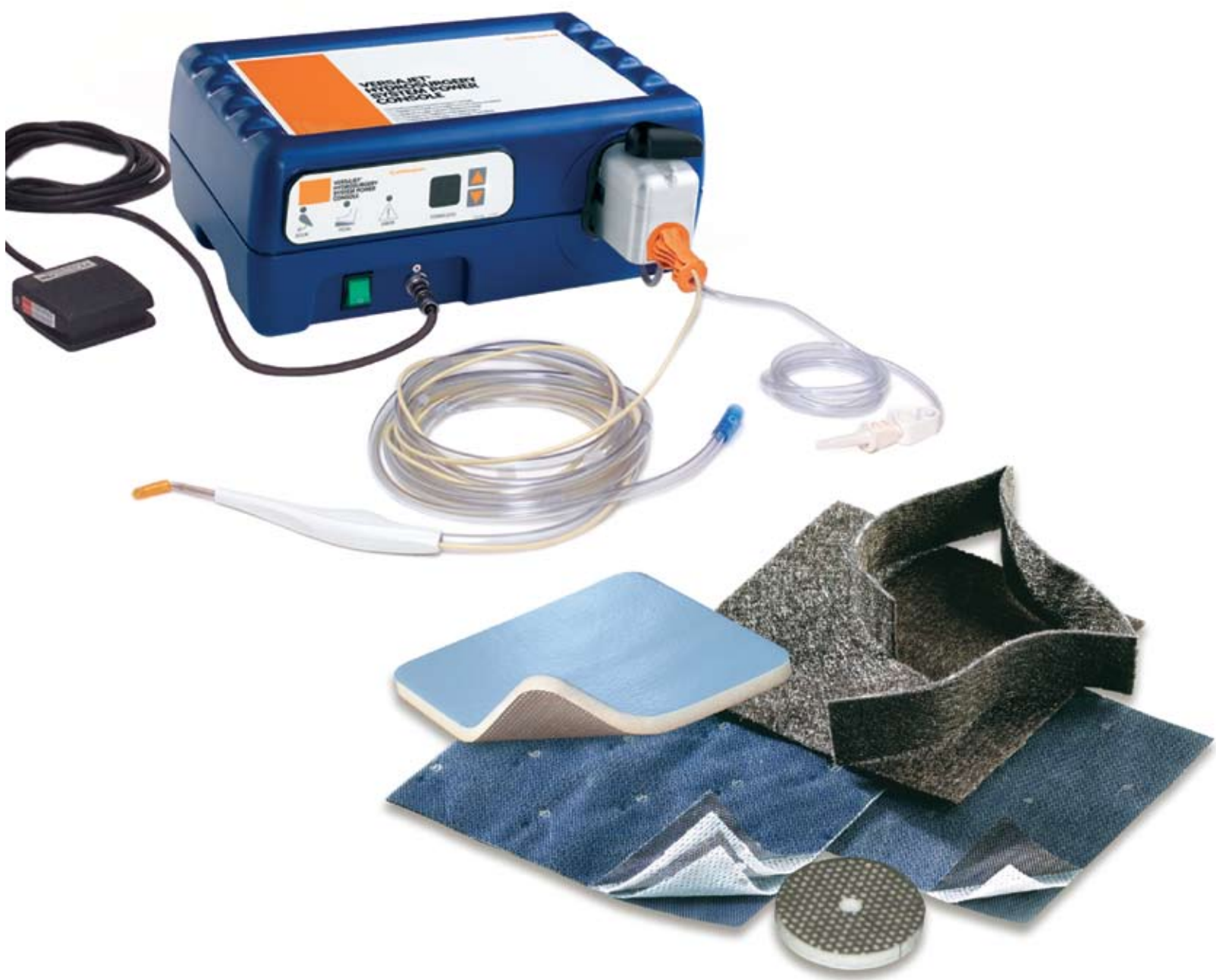Case Studies

Presented at the John A. Boswick
Burn and Wound Care Symposium, Maui



VERSAJET◊
Hydrosurgery System

ACTICOAT◊
Silver-Coated
Antimicrobial Barrier
SILCRYSTSM
NANOCRYSTALS



Management of a pediatric facial burn with VERSAJET[◇] and ACTICOAT[◇]

Roselle E. Crombie, MD, MPH, Philip E. Fidler, MD, John T. Schulz, MD, PhD;
Bridgeport Hospital/Yale New Haven System, Andrew J. Pannetieri Burn Unit, Bridgeport, CT

Introduction

The use of VERSAJET and ACTICOAT in burn care are currently emerging as useful tools for the debridement and antimicrobial treatment of burn wounds. We are presenting a case of a facial partial thickness burn in an infant where we successfully utilized VERSAJET for our burn debridement followed by ACTICOAT for post op dressings with an excellent result.

Patient

Patient is an 11-month-old female who crawled up to an unprotected lamp sitting on the floor and sustained a partial thickness burn to the skin surrounding her left eye, left zygoma region and a small patch on her left cheek. After 24 hours, it became clear that the lateral aspect of the skin surrounding her left eye, part of her eyebrow region, and interior to the eye was a deeper burn requiring debridement of eschar and possible grafting (figure 1).

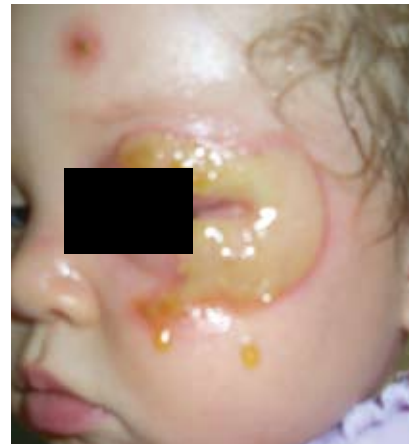

Figure 1

Treatment

The patient was taken to the operating room, underwent debridement of this deeper burn with VERSAJET and the wound bed was dressed with ACTICOAT. Operating time was less than one hour with minimal blood loss. Patient was discharged to home with the 3 day ACTICOAT in place on the same day of surgery.

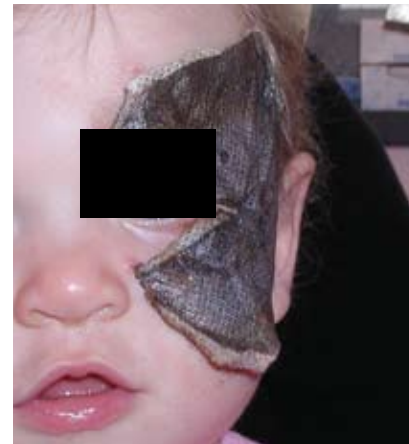

Figure 2

Outcome

Patient was seen in the office 3 days post-op at which time ACTICOAT was removed and she was examined. Patient had excellent granulation tissue in place and no signs of infection. (see figure 2). The patient was seen in follow up 10 days post op with the area of debridement well healed, no evidence of uneven step off with surrounding normal tissue and minimal redness (figure 3).

Conclusion

VERSAJET is an excellent instrument for burn debridement on the face and other areas with complex topology and functionally severe consequences of overexcision. The energy conveyed by the instrument and the pressure applied by the surgeon can be varied as needed to remove eschar without destruction of underlying viable tissue and VERSAJET is small enough to fit into tight corners. VERSAJET allowed us to precisely excise this child's burn eschar with minimal sacrifice of healthy tissue and to discharge the patient home on the same day of surgery without complication. Dressing the wound with the silver impregnated ACTICOAT dressing created an antimicrobial environment which in turn allowed the bed to heal quickly with minimal scar in just 10 days (figure 3).

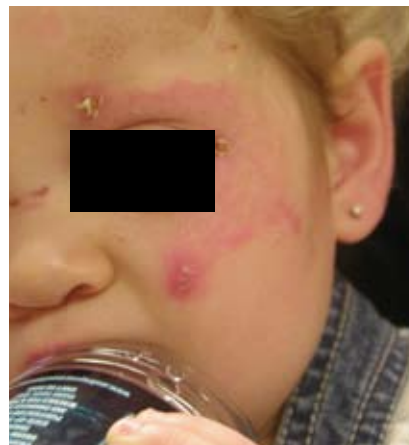

Figure 3

Conservative management of a deep partial thickness hand burn treated with VERSAJET[◇] and ACTICOAT[◇]

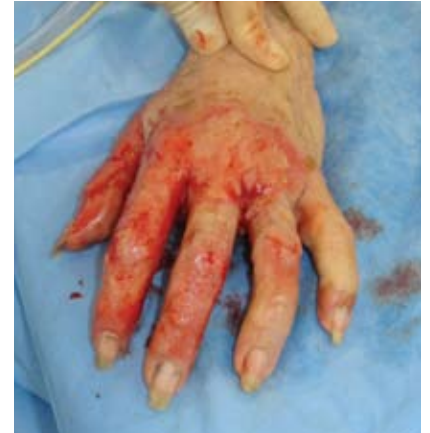Roy R. Danks, DO, General, Trauma and Burn Surgery. Kansas Surgical Consultants, Wichita, KS

Introduction

The patient is a 79 y.o. female with multiple medical conditions. She was on chronic oral steroids for pulmonary disease. She sustained a deep partial thickness hand burn secondary to a grease scald. It was treated conservatively by a primary care physician for several weeks, but failed to heal well.

When seen in the outpatient burn clinic, the burn was clearly deep, but was showing some signs of secondary healing, including some dermal buds and marginal re-epithelialization. At the time she was seen, the burn was more than 3 weeks old.

Her non-burned skin was very fragile and thin in most areas. She had significant risk factors for complications should general anesthesia be required.

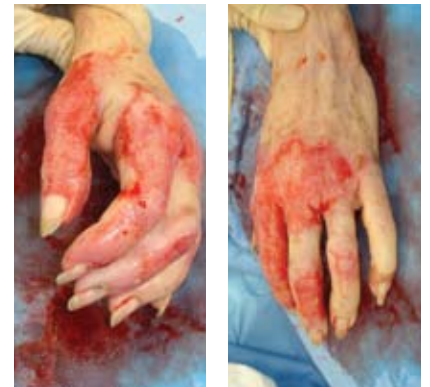

Patient's hand at presentation

Treatment

The decision was made to perform VERSAJET debridement and placement of BIOBRANE[®] covered with ACTICOAT.

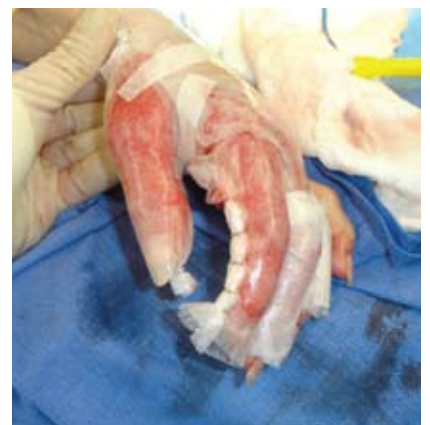Surgery was successfully performed using IV sedation. Excellent debridement of the burn eschar was achieved with VERSAJET on a power level setting of 3. BIOBRANE[®] and ACTICOAT were then applied.



Patient's hand after VERSAJET

Follow-up

When seen in clinic one week post-operatively, the wound was healing well with almost complete re-epithelialization and no signs of infection. 2 weeks post-op the BIOBRANE[®] was completely removed, revealing complete wound closure. There was minimal scarring and no discernible loss of hand function.



Patient's hand after VERSAJET with BIOBRANE[®]

Combined use of VERSAJET[◇] and ACTICOAT[◇] for the management and debridement of a full-thickness flame burn to the right hand

Shaher Khan, MD, Burn Fellow, Philip Fidler, MD, John T. Schulz, MD, PhD, Nabil Atweh, MD; Andrew J. Panettieri Burn Center, Bridgeport Hospital, CT, Yale University, Department of Surgery

Introduction

This case illustrates the combined use of VERSAJET and ACTICOAT in the debridement and management of a full-thickness flame burn to the right hand.

Patient

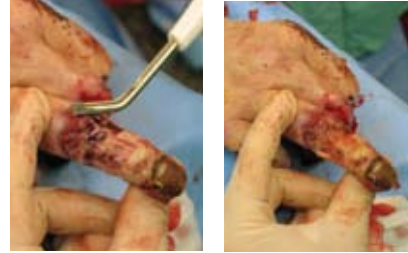A 49-year-old right-handed male was transferred to the burn center with full-thickness burns to the right forearm and hand, left elbow, and bilateral lower extremities. These severe flame burns were sustained after the patient poured gasoline on a smoldering campfire resulting in his clothes catching on fire.

Treatment

Upon arrival in the burn unit, ACTICOAT dressings were applied to the aforementioned areas (~3000 cm²). ACTICOAT was moistened in sterile water and wrapped with Kerlex rolls. On hospital day #4 the patient was taken to the OR and xenografts were applied followed by reapplication of the ACTICOAT dressings to the aforementioned areas. On hospital day #9 the patient was allografted at the right hand and leg.

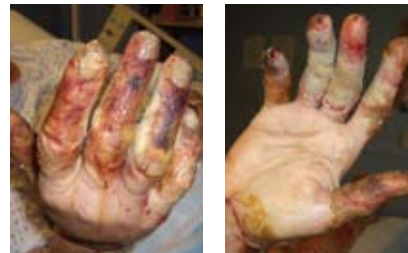On hospital day #20 hydrodissection was carried out using VERSAJET on the full-thickness burns to the hand. After the necrotic tissue was removed, the surgery proceeded rapidly with efficient debridement of necrotic tissue to the required depth using continued, gentle strokes with the VERSAJET handpiece on a power level setting of 5.

VERSAJET allowed for excision and evacuation of damaged tissue/contaminants while simultaneously irrigating the wound. Surgical debridement was accomplished in a single step. Further, the device utilized a relatively small amount of irrigant which immediately was evacuated, minimizing saturation of the operative field and reducing the risk of splashing and aerosolisation. VERSAJET was seen to be the most discerning methodology for debridement, allowing only clearly necrotic tissue to be excised. This method made it possible to salvage as much tissue as possible for future reconstruction.

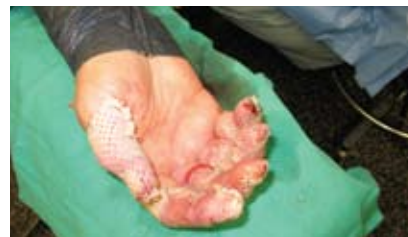

Sweeping motion of the VERSAJET (Power setting: 5)

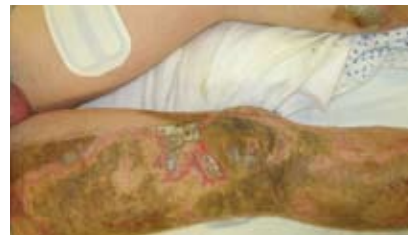Treatment by VERSAJET



Xenografting of right hand with serial applications of ACTICOAT[◇]



Xenografting followed by re-application of ACTICOAT



Application of ACTICOAT to leg burn prior to Xenografting

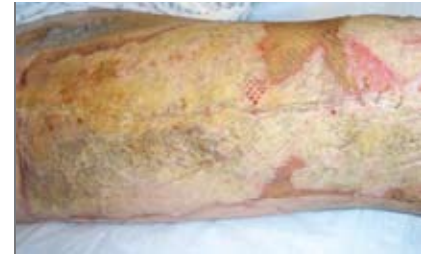Outcome

The patient subsequently had a split thickness skin graft (STSG) to the hand which healed successfully without any infection.

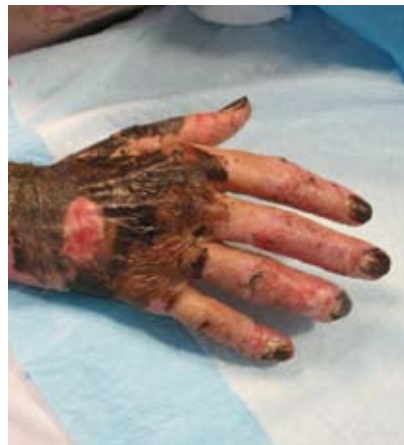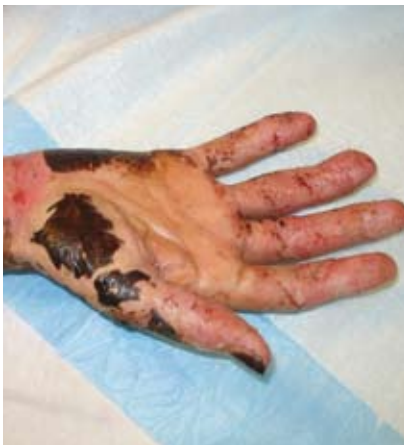The water dissector provided a facile method of excising burns in critical, yet challenging anatomic areas such as the fingers. The VERSAJET Hydrosurgery System not only substantially simplified the debridement of 3rd and 4th degree burns but also allowed for rapid and precise excision, sparing healthy tissue and promoting healing.

Wound debridement using VERSAJET® is efficient and straightforward, reducing operative time. It allows for surgical debridement while providing concurrent lavage, minimizing exposure to droplet aerosolisation in the operating suite.

With the VERSAJET System, tissue excision is precise, avoiding damage to healthy tissue or vasculature. Also, the design of the handpiece allows access for debridement without the need to enlarge the wound, reducing postoperative morbidity and promoting wound healing.



Xenografting followed by re-application of ACTICOAT



Long term follow-up: split-thickness autograft

References

1. "Transection of the liver with a water jet." Persson BG, Jeppsson B, Tranberg K-G, Roslund K, Bengmark S. *Surg Gynecol Obstet* 1989;168:267-8.
2. "Hydro-Jet-assisted laparoscopic cholecystectomy: a prospective randomized clinical study." Shekarriz H, Shekarriz B, Kujath P, et al. *Surgery* 2003;133:635-40.
3. "The diagnosis of the depth of burning" D.M. Jackson, *Br J Surg* 40 (1953), pp. 588-596.
4. "Wound Debridement Using VERSAJET A Novel Hydrosurgery System", Hsu, Christina and Breuing, Karl, *HydroCision Doc. No. 1000-1232 Rev A 09/03*.
5. "Traumatic and Chronic Wound Debridement with a Novel Fluidjet Device: The VERSAJET Hydrosurgery System", Tortella, Bartholomew J., *HydroCision Doc. No. 1000-1249 Rev A 08/03*.
6. "Fluidjets in Surgery", Freeman, D.C., Jr., and Moutafis, T.E.
7. "A Pilot Study of Two Techniques for Wound Debridement", Webb, Lawrence X., et al, *HydroCision Doc. No. 1000-1255, Rev. A 09/03*.
8. "Wound Debridement: A Comparison for Two Techniques for Particle Clearance", Webb, Lawrence X., et al, *HydroCision Doc. No. 1000-1161, Rev. A 09/03*.
9. "High Pressure Parallel Fluid Flow for Debridement of Contaminated Wounds in a Pig Model", Webb, Lawrence X., et al, *HydroCision Doc. No. 1000-1173, Rev. A 01/03*.
10. "A Phenomenological Description of Fluidjet Cutting", Freeman, D.C., Jr., and Moutafis, T.J., *HydroCision Doc (unnumbered) Rev. 07/02*.
11. "Use of the VERSAJET Hydrosurgery System on a Burn Victim", Tortella.
12. "Aerosol Study", Webb, Lawrence X., et al, *HydroCision Doc. No. 1000-1172, Rev. A 09/03*.
13. "Silver absorption and antibacterial efficacy of silver dressings." *J Wound Care.* 2005 Apr;14(4):155-60.
14. "Therapeutic efficacy of three silver dressings in an infected animal model." *J Burn Care Rehabil.* 2005 Jan-Feb;26(1):53-6.
15. "The truth about silver." *Ostomy Wound Manage.* 2004 Sep;50(9A Suppl):1S-10S. Review
16. "The role of ACTICOAT with nanocrystalline silver in the management of burns." *Burns.* 2004 Jul;30 Suppl 1:S1-9. Review.
17. "An overview of ACTICOAT dressing in wound management." *Br J Nurs.* 2003 Oct;12(19 Suppl):S44-9.
18. "Assessment of a silver-coated barrier dressing for potential use with skin grafts on excised burns." *Burns.* 2003 Aug;29(5):445-8.
19. "The rate of re-epithelialization across meshed skin grafts is increased with exposure to silver." *Burns.* 2002 May;28(3):264-6.
20. "Comparative evaluation of the antimicrobial activity of ACTICOAT antimicrobial barrier dressing". *J Burn Care Rehabil.* 1999 May-Jun;20(3):195-200.
21. "A matched-pair, randomized study evaluating the efficacy and safety of ACTICOAT silver-coated dressing for the treatment of burn wounds." *J Burn Care Rehabil.* 1998 Nov-Dec;19(6):531-7.
22. "A silver-coated dressing reduces the incidence of early burn wound cellulitis and associated costs of inpatient treatment: comparative patient care audits." *Burns.* 2005 Aug;31(5):562-7. Epub 2005 Feb 17.
23. "The use of silver coated dressings on donor site wounds: a prospective, controlled matched pair study." *Burns.* 2001 Sep;27(6):621-7.

The VERSAJET[◇] hydrosurgery instrument and ACTICOAT[◇] have a role in large TBSA indeterminate and full thickness burns: A case report

Drew Davis, MD, Kenneth Yim, MD, Yvonne Karanas, MD; Santa Clara Valley Hospital Burn Unit, Santa Clara, CA

Introduction

Patients with large total body surface area burns present the burn surgeon with multiple challenges. When the burns are extensive and involve both deep partial thickness and full thickness depth, the control of bacterial load is paramount in the prevention of sepsis¹ and ultimately wound healing and graft take.² If it appears that large areas will ultimately require autografting for definitive coverage, careful and thoughtful surgical planning is needed to maximize the potential of precious donor sites.

In this case report, we describe our experience with the use of the water debridement system, VERSAJET, and the silver antimicrobial dressing, ACTICOAT, to approach both of these challenges. We report their combined utility in large surface area tangential excisions (80% total body surface area TBSA) to control bacterial load and to maximize potential for burns of unclear depth to heal primarily without autografting. With multiple tangential excisions with VERSAJET, allograft coverage, and ACTICOAT dressing, primary healing was achieved in areas that initially appeared full thickness and would have otherwise been excised and grafted.

Patient

The patient is a 17 year old healthy boy without prior past medical or surgical history who was caught in a structure fire and sustained an 80% flame burn to his face, neck, chest, back, circumferential bilateral upper extremities, hands, and circumferential bilateral lower extremities from the knees to the toes. His initial evaluation showed no other injuries. He was intubated in the emergency room for airway protection and admitted to the burn unit. Escharotomies were performed on his right arm and both of his legs and all burns were initially dressed with Silvadene. Fluid resuscitation followed the modified Parkland formula with the administration of 23 liters of lactated rings over the first 24 hours.

Treatment

Over the next 11 days, the patient was brought to the operating room for serial tangential excision of all burn sites except the face. All tangential excision was performed with VERSAJET, and the wound bed was always covered with allograft and dressed with ACTICOAT. On post-burn day 5, he began to have daily fevers of approximately 103.0F but remained hemodynamically stable without signs of systemic sepsis. Wound and blood cultures grew *Serratia*, and he was treated with 7 days of intravenous antibiotics. Both the arms and the legs were re-excised with VERSAJET, allografted, and dressed with ACTICOAT. Repeat cultures showed no bacterial growth. On post burn day 16, his legs were excised a third and final time with VERSAJET in combination with Eschman blades, autografted, and dressed again with ACTICOAT. The patient's face, chest, back, hands, and left arm all healed primarily. A small area on his right arm required subsequent excision and autografting.

Patient at presentation

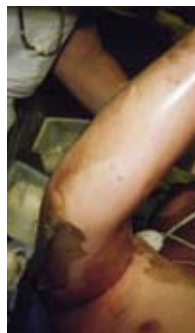

Figure 1. Patient's arm at presentation.

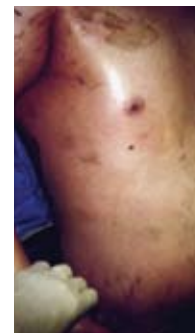

Figure 2. Patient's chest at presentation.



Figure 3. Patient's lower back at presentation.

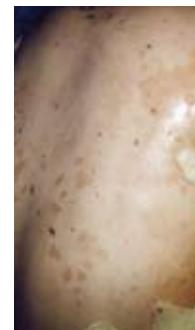

Figure 4. Patient's upper back at presentation.

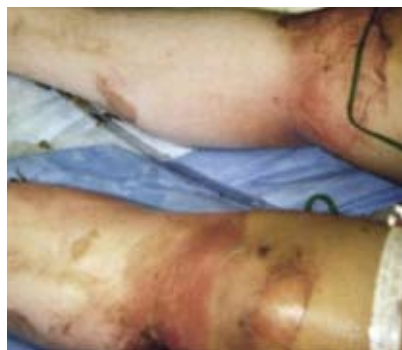

Figure 5. Patient's legs at presentation.

He was extubated 3 weeks after admission, and post-burn day 44 was transferred to the physical medicine and rehabilitation service. At transfer he was eating, ambulating, and requiring only oral pain medications. He was discharged to home post-burn day 62.

Conclusion

The treatment of extensive burns requires judicious use of scarce donor sites. In these situations, allowing deep partial thickness burns to heal primarily decreases the wound size needing coverage and preserves donor sites for deeper burns. As eluded to in the case report, it is often difficult to determine which indeterminate thickness burns will heal primarily and which will require grafting. Ideally, sharp tangential excision with Weck and Eschman blades is designed to resect only necrotic tissue and preserve viable tissue. Although more precise than other techniques, it is still operator dependent and may result in over or under excision.

Recently, VERSAJET® has been described as a useful tool to perform tangential excision on challenging anatomic areas such as the eyelids and webspaces, as well as preparing small burns (0.5-5% TBSA) for split thickness skin graft (STSG) or BIOBRANE® dressing.³⁻⁴ This case report illustrates that VERSAJET has utility in extensive burns on all parts of the body. It has been our experience that it allows for precise excision of burn eschar where the surgeon can control the depth of excision by millimeters by adjusting both the speed of the flow of water and the pressure of the handpiece against the skin. The vacuum effect created at the tip of instrument continuously suctions blood and the viability of the underlying tissue (dermis, fat, fascia, etc) is immediately and easily assessed.

Three days post-burn, approximately 70% TBSA (80% of the burn) appeared to be full thickness (Figures 1-5 show the burn at presentation). If we had sharply excised all these areas with traditional means, we undoubtedly would have over excised areas of viable tissue and would have created a much larger surface area in need of grafting.

During his hospital course, the patient was bacteremic but never became septic. We attribute this partly to the use of intravenous antibiotics, but also to the serial excisions done with VERSAJET and the antimicrobial properties of ACTICOAT®. Because of the precision of the depth of the debridement, we were able to excise only the most superficial layer of the wound bed thus controlling bacterial burden and not unnecessarily excising healthy tissue.

When seen in clinic 6-weeks post-operatively, the pt was making marked improvement with PT and OT, and he was healing well (Figures 6-9).

Since this case, we have used VERSAJET in combination with ACTICOAT on over thirty burn cases. We have found that allowing the eschar to soften with several days of treatment with either Silvadene or Accuzyme® makes the initial tangential excision easier. Also, the operative time to excise the eschar with the VERSAJET is not significantly longer than traditional excision with a Weck or Eschman blade.

VERSAJET and ACTICOAT clearly have a role in the surgical management of large surface area deep-partial and full-thickness burns. VERSAJET's ability to perform a precise, controlled tangential excision can be used in conjunction with ACTICOAT to control bacterial infection on the wound bed and to maximize the potential for indeterminate burns to heal primarily.

Patient at 6 weeks post-op

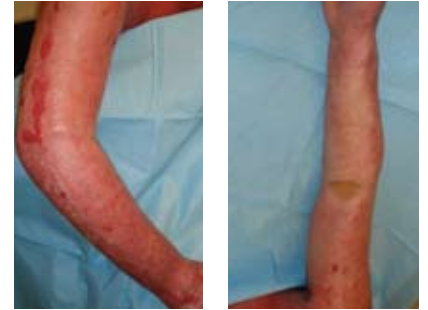


Figure 6. Patient's right arm 6 weeks post-op which healed primarily except for a small area (<1%) on the posterior upper arm.

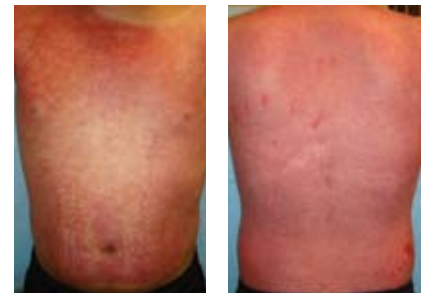


Figure 7. Patient's chest 6 weeks post-op which healed primarily.

Figure 8. Patient's back 6 weeks post-op which healed primarily.

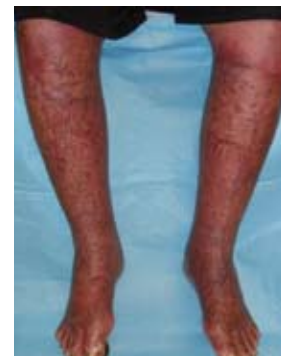

Figure 9. Patient's legs 6 weeks post-op after circumferential STSG.

References

1. Church, et al. Burn wound infections. Clin Micro Rev. 2006;19:403-434.
2. Robson MC, Krizek TJ. Predicting skin graft survival. J Surg Res 1973;13:213-7.
3. Klein, MB et al. The VERSAJET water dissector: a new tool for tangential excision. J Burn Care Rehabil 2005;26:483-487
4. Rennekampff, H et al. Debridement of burn wounds with a water jet surgical tool. Burns 2006;32:64-69.

Combined use of VERSAJET[◇] and ACTICOAT[◇] for management and debridement of full-thickness contact burns to the face, hand, and chest

Shaher Khan, MD, Burn Fellow, Philip Fidler, MD, John T. Schulz MD, PhD, Nabil Atweh, MD; Andrew J. Panettieri Burn Center, Bridgeport Hospital, CT, Yale University, Department of Surgery

Introduction

This case illustrates the combined use of VERSAJET and ACTICOAT in the debridement and management of full-thickness contact burns to the face, hand, and chest.

Patient

A 47 year old female was transferred to the burn center after a motor vehicle accident with 4th degree contact burns to the face, palmer surface of the right hand, and to the left breast/chest along with multiple serious traumatic injuries. In addition to her burns, other injuries included a C-1 fracture of the left lateral arch, pneumothoraces, a grade 3 liver laceration, a grade 1 splenic laceration, and pelvic fractures.

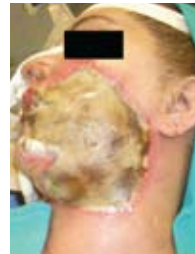Treatment

On hospital day #7 hydrodissection was carried out using VERSAJET on the 4th degree burns to the left face, hand, and chest/breast. After the necrotic tissue was removed, surgery proceeded rapidly with efficient debridement of necrotic fat to the required depth using continued, gentle strokes with the VERSAJET handpiece on a setting of 4.

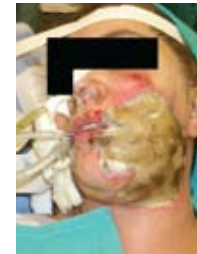VERSAJET allowed for excision and evacuation of the damaged tissue/contaminants while simultaneously irrigating the wound. Surgical debridement was accomplished in a single step. Further, the device utilized a relatively small amount of irrigant which immediately was evacuated, minimizing saturation of the operative field and reducing the risk of splashing and aerosolisation. The patient then had reapplication of the homograft to the face, hand, and breast followed by application of ACTICOAT moistened in sterile water.

Further hydrodissection on the aforementioned areas was carried out 3 days later using VERSAJET where devitalized tissue was excised with precision again at a setting of 4. After application of the homografts, 3-day ACTICOAT moistened in sterile water was then reapplied. The right hand was allowed to heal using topical negative pressure.

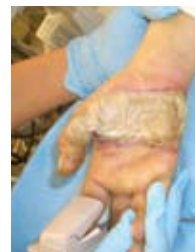On hospital day #26 another application of VERSAJET was utilized for sharp debridement of a wound that continued to declare itself. VERSAJET was seen again to be the most discerning methodology for debridement. Like before, the only clearly necrotic tissue was excised. All attempts were made to salvage as much tissue as possible for future reconstruction.



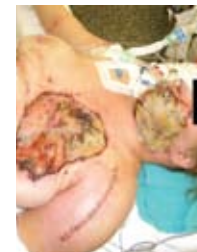Full-thickness burn to face/neck



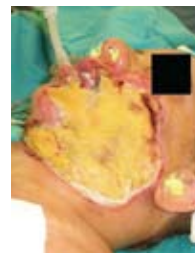Full-thickness burn to face/neck



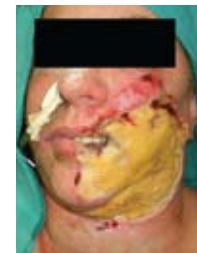Full-thickness burn to right hand



Prior to use of VERSAJET



After debridement with VERSAJET, before application of ACTICOAT



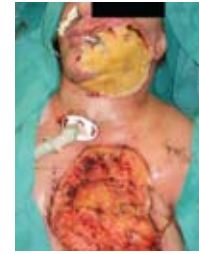Outcome

On hospital day #32 the patient had a split thickness skin graft (STSG) application to the chest/breast along with the right hand which healed well without an infection. Serial ACTICOAT® dressings were again used for the face. The patient subsequently had a bilayer matrix wound dressings applied to the face followed by ultra-thin autograft placement.

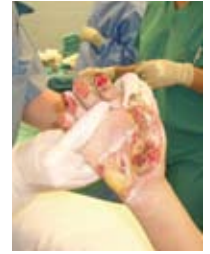The water dissector provided a facile method of excising burns in critical, yet challenging anatomic areas, such as the face, hand, and breast tissue. The VERSAJET® Hydrosurgery System not only substantially simplified the debridement of 3rd and 4th degree burns but also allowed for rapid and precise excision, sparing healthy tissue and promoting healing.

Wound debridement using VERSAJET is efficient and straightforward, reducing operative time. It allows for surgical debridement while providing concurrent lavage, minimizing exposure to droplet aerosolisation in the operating suite.

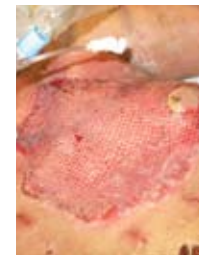With the VERSAJET System, tissue excision is precise, avoiding damage to healthy tissue or vasculature. Also, the design of the handpiece allows access for debridement without the need to enlarge the wound, reducing postoperative morbidity and promoting wound healing.



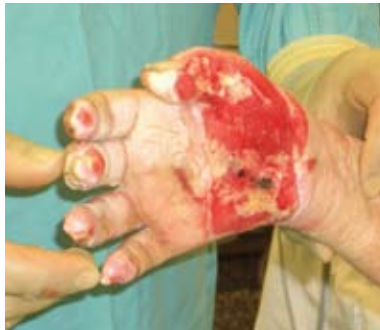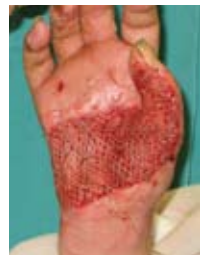After VERSAJET application



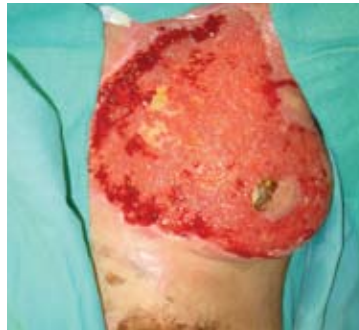After VERSAJET treatment before application of ACTICOAT and topical negative pressure



Split-thickness autograft



After applications of VERSAJET, and ACTICOAT and Negative Pressure Wound Therapy



VERSAJET treatment and ACTICOAT application

References

1. "Transaction of the liver with a water jet." Persson BG, Jeppsson B, Tranberg K-G, Roslund K, Bengmark S. *Surg Gynecol Obstet* 1989;168:267-8.
2. "Hydro-Jet-assisted laparoscopic cholecystectomy: a prospective randomized clinical study." Shekarriz H, Shekarriz B, Kujath P, et al. *Surgery* 2003;133:635-40.
3. "The diagnosis of the depth of burning" D.M. Jackson, *Br J Surg* 40 (1953), pp. 588-596.
4. "Wound Debridement Using VERSAJET A Novel Hydrosurgery System", Hsu, Christina and Breuing, Karl, *HydroCision Doc. No. 1000-1232 Rev A 09/03*.
5. "Traumatic and Chronic Wound Debridement with a Novel Fluidjet Device: The VERSAJET Hydrosurgery System", Tortella, Bartholomew J., *HydroCision Doc. No. 1000-1249 Rev A 08/03*.
6. "Fluidjets in Surgery", Freeman, D.C., Jr., and Moutafis, T.E.
7. "A Pilot Study of Two Techniques for Wound Debridement", Webb, Lawrence X., et al, *HydroCision Doc. No. 1000-1255, Rev. A 09/03*.
8. "Wound Debridement: A Comparison for Two Techniques for Particle Clearance", Webb, Lawrence X., et al, *HydroCision Doc. No. 1000-1161, Rev. A 09/03*.
9. "High Pressure Parallel Fluid Flow for Debridement of Contaminated Wounds in a Pig Model", Webb, Lawrence X., et al, *HydroCision Doc. No. 1000-1173, Rev. A 01/03*.
10. "A Phenomenological Description of Fluidjet Cutting", Freeman, D.C., Jr., and Moutafis, T.J., *HydroCision Doc (unnumbered) Rev. 07/02*.
11. "Use of the VERSAJET Hydrosurgery System on a Burn Victim", Tortella.
12. "Aerosol Study", Webb, Lawrence X., et al, *HydroCision Doc. No. 1000-1172, Rev. A 09/03*.
13. "Silver absorption and antibacterial efficacy of silver dressings." *J Wound Care*. 2005 Apr;14(4):155-60.
14. "Therapeutic efficacy of three silver dressings in an infected animal model." *J Burn Care Rehabil*. 2005 Jan-Feb;26(1):53-6.
15. "The truth about silver." *Ostomy Wound Manage*. 2004 Sep;50(9A Suppl):1S-10S. Review
16. "The role of ACTICOAT with nanocrystalline silver in the management of burns." *Burns*. 2004 Jul;30 Suppl 1:S1-9. Review.
17. "An overview of ACTICOAT dressing in wound management." *Br J Nurs*. 2003 Oct;12(19 Suppl):S44-9.
18. "Assessment of a silver-coated barrier dressing for potential use with skin grafts on excised burns." *Burns*. 2003 Aug;29(5):445-8.
19. "The rate of re-epithelialization across meshed skin grafts is increased with exposure to silver." *Burns*. 2002 May;28(3):264-6.
20. "Comparative evaluation of the antimicrobial activity of ACTICOAT antimicrobial barrier dressing". *J Burn Care Rehabil*. 1999 May-Jun;20(3):195-200.
21. "A matched-pair, randomized study evaluating the efficacy and safety of ACTICOAT silver-coated dressing for the treatment of burn wounds." *J Burn Care Rehabil*. 1998 Nov-Dec;19(6):531-7.
22. "A silver-coated dressing reduces the incidence of early burn wound cellulitis and associated costs of inpatient treatment: comparative patient care audits." *Burns*. 2005 Aug;31(5):562-7. Epub 2005 Feb 17.
23. "The use of silver coated dressings on donor site wounds: a prospective, controlled matched pair study." *Burns*. 2001 Sep;27(6):621-7.

Management of severe pediatric facial, neck and hand burns with VERSAJET[◇] and ACTICOAT[◇]

Roselle E. Crombie, MD, MPH, Philip E. Fidler, MD, John T. Schulz, MD, PhD;
Bridgeport Hospital/Yale New Haven System, Andrew J. Pannetieri Burn Unit, Bridgeport, CT

Introduction

We are presenting a case of a facial, neck, and hand partial and full thickness burn in a child where we successfully utilized VERSAJET for our multiple burn debridements followed by repeated applications of ACTICOAT for post op dressings with good functional and cosmetic result.

Patient

Patient is a 7 y.o. boy who sustained 2nd and 3rd degree injuries to his face, neck and left hand when his Halloween costume caught fire. Because of his resuscitation and distribution of his injuries, the patient was intubated on arrival to the hospital. Within his first 24 hours, he was taken to the OR for his initial burn debridement (figure 1 & 1A). He had debridement of his face with conventional methods and escharotomies to his left hand at this surgery. An ACTICOAT mask was fashioned to cover his face and neck (figure 2). ACTICOAT was also applied to his hand. His 2nd surgery occurred three days later where we used VERSAJET at this time to debride the area of 3rd degree burn on his right neck (Figure 3). The patient underwent two subsequent surgeries in the following two weeks to engraft his neck, chin and left hand. All sheet grafts were dressed with ACTICOAT.

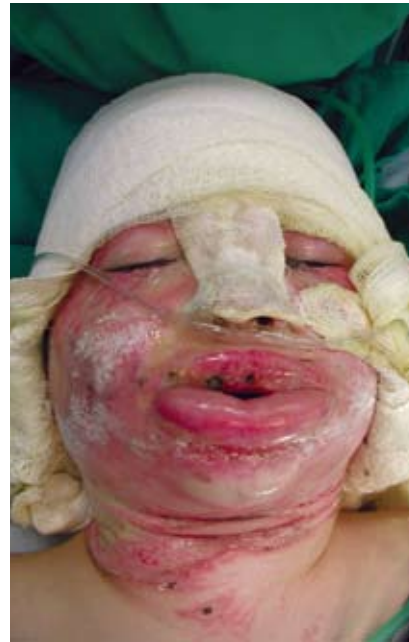

Figure 1

Results

Patient had 90-95% take of engraftment on his neck, chin, and left hand. VERSAJET enabled us to precisely and meticulously debride eschar from his chin and neck that we would not have been able to do with the conventional Weck knife or sharp debridement. Time to completed closure was less than two weeks from engraftment. ACTICOAT allowed us to maintain a non-infected environment for the grafts to heal. Using ACTICOAT for 7 days allowed healing without daily dressing changes and hence less narcotic use. Patient was discharged 29 days post injury with all areas closed (epithelialized) (figure 4). Now 2 years out from injury, patient has good functional and cosmetic result given the depth and severity of his injury (figure 5 & 6).

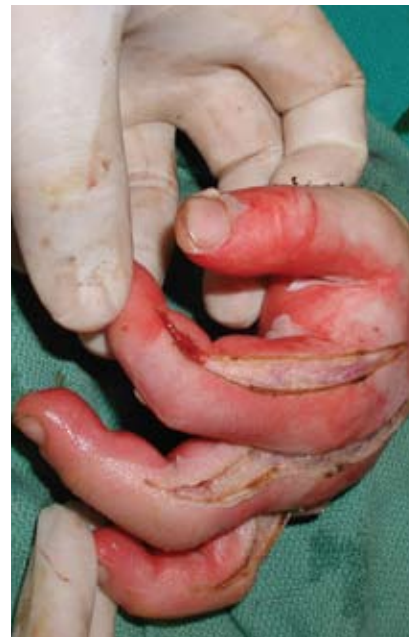

Figure 1a

Conclusion

VERSAJET® is an excellent instrument for burn debridement on the face and other areas with complex topology and functionally severe consequences of overexcision. The energy conveyed by the instrument and the pressure applied by the surgeon can be varied as needed to remove eschar without destruction of underlying viable tissue. The VERSAJET handpiece is small enough to fit into tight corners allowing for a more precise excision. VERSAJET allowed us to precisely excise this child's burn eschar with minimal sacrifice of healthy tissue. Dressing the wound with the silver impregnated ACTICOAT® dressing created an antimicrobial environment which in turn allowed the bed to heal quickly given this severe injury.

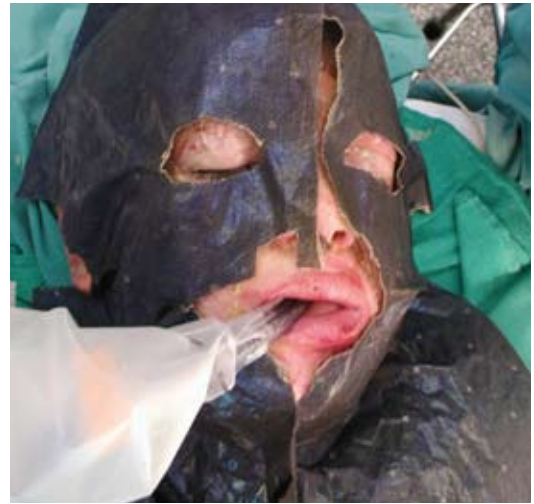

Figure 2

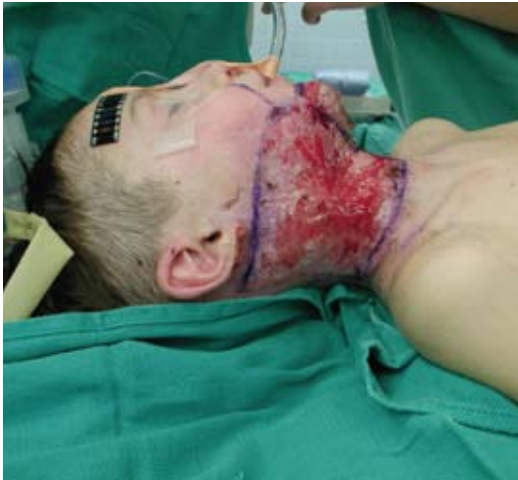

Figure 3

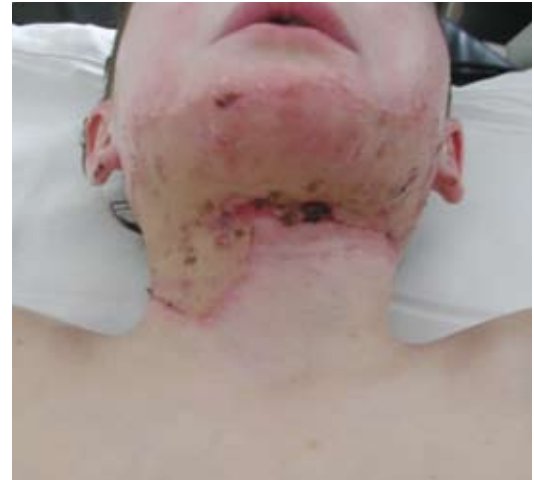

Figure 4

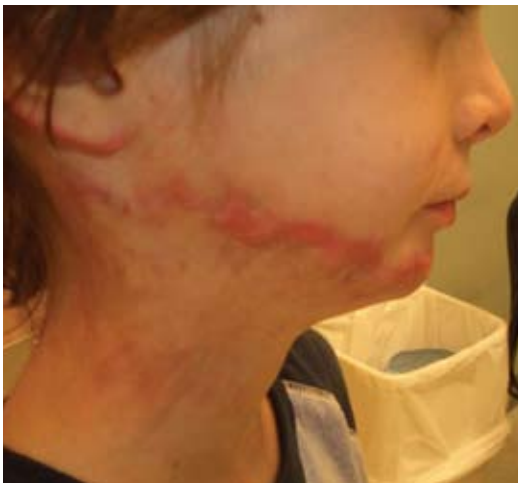

Figure 5

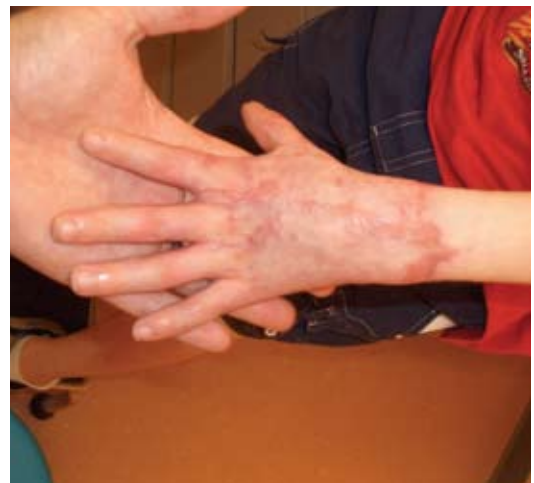

Figure 6

**EU Authorised
Representative**

Wound Management

Smith & Nephew
Medical Ltd
101 Hessle Road
Hull HU3 2BN
T 44 (0) 1482 225181f
F 44 (0) 1482 673106

Manufactured for:

Smith & Nephew Inc.
11775 Starkey Road
Largo, FL 33773
USA

www.smith-nephew.com/wound
www.acticoat.com
www.globalwoundacademy.com
www.versajet.info